

CASE REPORT

Pathologically and Bacteriologically Unconfirmed Esophageal Tuberculosis Diagnosed by Endoscopic Ultrasound Combined with the T-SPOT.TB test: A Case Report

Rui Huang, Suyu Chen, Juan Lin, Hong Shi*

Department of Endoscopy Center, Fujian Cancer Hospital and Fujian Medical University Cancer Hospital, Fuzhou, Fujian, China

Abstract: Esophageal tuberculosis (TB) is relatively a rare disease, and its diagnosis is often unknown due to the lack of specific clinical symptoms and endoscopic manifestations, as well as the low success rate of pathological biopsy. In this case report, we describe a patient who presented with dysphagia as the chief complaint, manifested as a submucosal eminence under endoscopy. Endoscopic ultrasonography showed hypoechoic changes, disappearance of some layers and esophageal boundaries, and echo of fused lymph nodes around the esophagus. The patient had strongly positive results of the purified protein derivative skin test and T-SPOT.TB. Subsequently, the patient received treatment of anti-TB drugs, and the clinical symptoms improved. According to the patient's medical history and endoscopic ultrasonography results, esophageal TB was the most probable diagnosis. Therefore, this case report offers new ideas that endoscopic ultrasonography and a review of clinical manifestations can be used to diagnose esophageal TB.

Keywords: Endoscopic ultrasonography, Esophageal tuberculosis, T-SPOT.TB, Purified protein derivative skin test

Received: June 5, 2021
Accepted: June 25, 2021
Published Online: July 21, 2021

***CORRESPONDING AUTHOR**
Hong Shi
Email: endoshihong@hotmail.com

CITATION
Huang R, Chen S, Lin J, *et al.*, 2021, Pathologically and Bacteriologically Unconfirmed Esophageal Tuberculosis Diagnosed by Endoscopic Ultrasound Combined with the T-SPOT.TB Test: A Case Report, *Gastroenterol Hepatol Lett*, 3(2):1-4.
DOI: [10.18063/ghl.v3i2.271](https://doi.org/10.18063/ghl.v3i2.271)

Copyright: © 2021 Huang, *et al.* This is an Open-Access article distributed under the terms of the Creative Commons Attribution-Non-Commercial 4.0 International License (<http://creativecommons.org/licenses/by-nc/4.0/>), permitting all non-commercial use, distribution, and reproduction in any medium, provided the original work is properly cited.

1. Introduction

At present, esophageal tuberculosis (TB) is a rare disease. At the same time, atypical symptoms and imaging manifestations, and the fact that it is difficult to diagnose, can often lead to misdiagnosis.^[1,2] In this case report, we describe a patient with esophageal TB.

2. Case report

The patient, a 58-year-old male, had dysphagia for more than 2 months. He denied a history of TB and had no symptoms of infection, such as fever. He underwent indirect inguinal hernia surgery 1 year prior and was prone to allergy. There was no obvious abnormality in the patient's physical examination.

Routine tests of urine specimen for hematuria and fecal specimens, biochemical tests, coagulation test, and tests for tumor markers showed normal results. The patient was tested negative for HIV, syphilis, and hepatitis B. He also has normal electrocardiogram and high erythrocyte sedimentation rate.

The patient was examined in a local hospital with endoscopy which showed a 2 cm × 2 cm swelling with a smooth mucosal surface approximately 35 cm from the incisor.

Pathological biopsy revealed chronic inflammation with low-grade intraepithelial neoplasia. Five days later, in the Fujian Province Cancer Hospital, endoscopy of the lesion showed hemispherical eminence with approximately 2 cm × 2.5 cm base, a soft texture, and rupture in the lesion's central surface (**Figure 1A**), which was considered by the local hospital to have formed after the biopsy. Longitudinal endoscopic ultrasonography examination of the esophageal lesions showed wall damage, low echogenic areas, partial disappearance of esophageal boundary, scattered lymph nodes around the esophagus, and partial fusion (**Figure 1B-D**). Biopsy was again performed at the same site, and pathological report revealed the infiltration of a large amount of inflammatory cells.

Plain computed tomography (CT) scan and enhancement of the esophagus showed thickening of

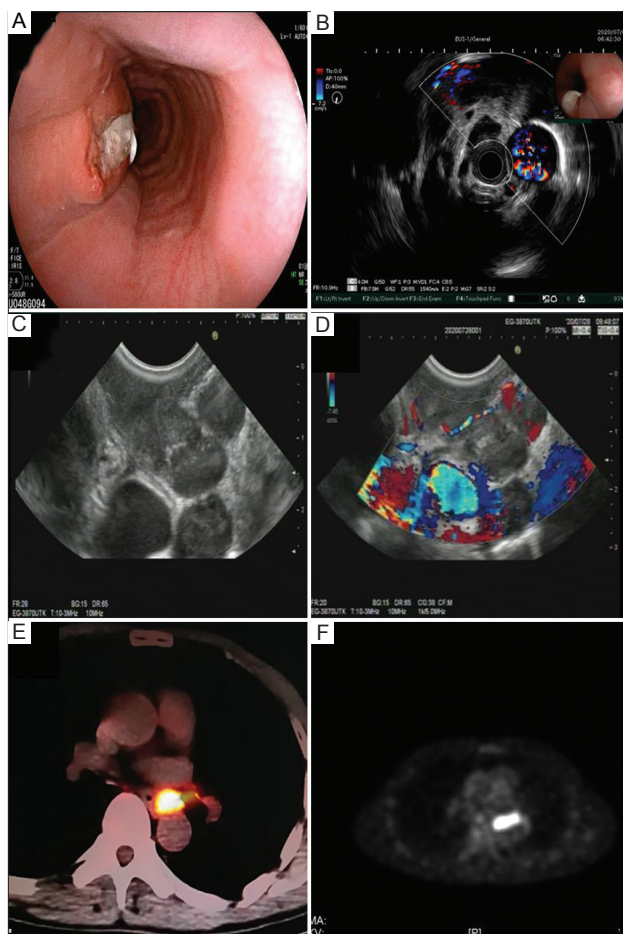


Figure 1. (A) Endoscopy of the lesion showed hemispherical eminence with approximately 2 cm × 2.5 cm base, a soft texture, and rupture in the lesion's central surface. (B-D) Endoscopic ultrasonography showed esophageal wall damage, low echogenic areas, partial disappearance of the esophageal boundary, scattered lymph nodes around the esophagus, and partial fusion. (E and F) Positron emission tomography-computed tomography examination showed thickening of local soft tissue in the middle and lower thoracic esophagus, high metabolic activity, and unclear boundary between soft tissue and left esophageal wall, suggesting a high possibility of malignant lesions.

the wall in the middle and lower thoracic esophagus and enlargement of several mediastinal lymph nodes, which ruled out the possibilities of metastatic tumor and granulomatous inflammation. Subsequently, positron emission tomography-CT examination showed thickening of local soft tissue in the middle and lower thoracic esophagus, high metabolic activity, and unclear boundary between soft tissue and left esophageal wall, which were suggestive of a high possibility of malignant lesions, such as esophageal cancer or metastatic lymph nodes. There were multiple lymph nodes in the mediastinum, behind the left lower lung ligament, behind the vena cava, around the upper trachea, and near the lesser curvature of the stomach. The possibility of metastasis was considered high given the increased metabolism (**Figure 1E and F**).

The result of purified protein derivative (PPD) test was strongly positive. While the T-SPOT.TB test result was positive, no acid-fast bacilli were found in sputum smears and the biopsies. For further diagnosis, endoscopic ultrasonography-guided fine-needle aspiration (EUS-FNA) biopsy was performed, in which the needle (ECHO-1-22) was punctured gently through the low echogenic areas using the door-knocking method. The specimens were sent for histopathologic examination, and the pathological results showed inflammatory exudation, necrosis, and granulation tissue hyperplasia. Polymerase chain reaction test for detecting *Mycobacterium tuberculosis* had negative result. The pathologic diagnosis was still not clear despite the completion of relevant examination, but combined with the medical history, the possibility of esophageal TB was considered high.

During hospitalization, the patient's symptoms improved after anti-infection treatment. After discharge, the patient was treated regularly for 2 months with anti-TB drugs, comprising of rifampicin, isoniazid, ethambutol, and pyrazinamide. The symptoms of swallowing discomfort disappeared. Reexamination using the endoscope showed that the swelling lesion had diminished (**Figure 2**). As of

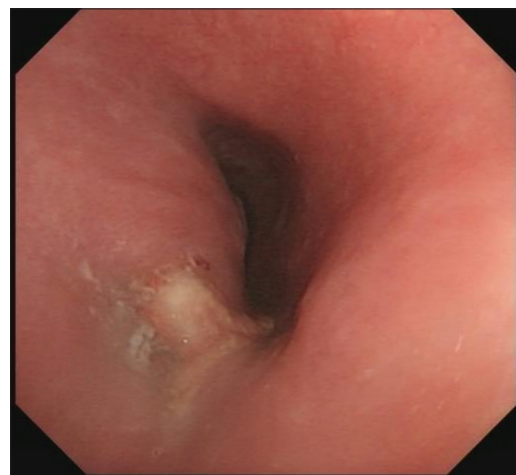

Figure 2. Endoscopic examination after 2 months of treatment with anti-tuberculosis drugs. The image shows diminished swelling lesion and visible, new granulation tissue.

April 2021, the patient has been under treatment with anti-TB drugs for 6 months, and we still followed up with him every 2 months.

Informed consent was obtained from the patient for being included in the study.

3. Discussion

Esophageal TB is rare in the clinical setting, but it has attracted the attention of clinicians due to the increasing incidence of TB in recent years. Despite its low rate of incidence, esophageal TB has been reported globally.^[1] This disease is mostly secondary to pulmonary TB and TB of the paraesophageal lymph node,^[2] while a small portion of cases are directly caused by MTB. Esophageal TB described in the current case report was very likely secondary to TB of paraesophageal lymph nodes. Besides, the patient also did not manifest typical symptoms, such as low-grade fever and night sweats, irrespective of pulmonary imaging manifestations, and displayed a low detection rate of TB from sputum smears.^[3] The lack of typical clinical symptoms and signs makes clinical diagnosis difficult.^[4] The common clinical manifestations of esophageal TB are dysphagia and retrosternal discomfort, which are mainly related to the narrowing of lumen caused by the lesion.^[5] The manifestations of lesions under endoscopy are diverse, including protruded type and ulcerated type; among which, the protruded type is more common. Different types of ulcerations can be found at different stages of TB.^[6] In the current case, there was a rupture in the surface of the submucosal eminence lesion due to biopsy, necessitating the discrimination of this lesion from esophageal leiomyoma, Crohn's disease, and esophageal cancer.^[7] At the same time, it is necessary to consider whether there are other sites of TB because there have been comorbidity cases of esophageal TB and colonic TB.^[8]

For the diagnosis of esophageal TB, pathological examination is the only criterion for definite diagnosis. However, esophageal TB is mostly located in the deep mucosa and submucosa, and the positive detection rate based on endoscopic biopsy is low in general. Some cases of esophageal TB are even confirmed after the operation, with no clear pathological diagnosis made before the operation. EUS and EUS-FNA have advantages in this regard. The characteristics of endoscopic ultrasonography for esophageal TB are summarized in the literature, and esophageal TB mostly manifests on EUS as incomplete esophageal walls and heterogeneous hypoechoic masses, with closely related enlarged lymph nodes visible outside the wall, some of which can be fused with each other.^[9-11] These manifestations are consistent with the disease in this case. However, obtaining histological specimens through EUS-FNA are beneficial for improving the diagnosis rate of esophageal TB, but the specimen in this case only indicated granulation tissue hyperplasia. Along with the endoscopic manifestations and endoscopic

ultrasonography findings of this patient, we also found that the PPD skin test and T-SPOT.TB test of the patient were both positive. Although there was no pathological evidence, the possibility of esophageal TB was still considered. A success in the improvement of the patient's symptoms following the empirical anti-TB treatment also confirmed the aforementioned diagnosis.

4. Conclusion

Esophageal TB often lacks typical clinical symptoms and endoscopic findings; therefore, clinical diagnosis based on pathologic examination can be difficult to make. Therefore, in the diagnosis and treatment of esophageal TB, screening should be performed. A failure in diagnosis would delay treatment, thereby affecting the quality of the patient's life. The current case also demonstrates that the empirical anti-TB treatment could deliver good clinical outcomes to the patient with esophageal TB. In addition, taking into account, the medical history and endoscopic ultrasound findings could help make reasonable diagnosis of esophageal TB so that misdiagnosis and unnecessary surgery can be avoided.

Conflicts of interest

The authors declare that they have no conflicts of interest.

Author contributions

All authors made substantial contributions to the acquisition of data and conception of the case report. R.H. wrote the manuscript and edited the final version of the manuscript before submission. All authors approved the final draft for publication.

Availability of data and materials

The data in the study are available from corresponding author on reasonable request.

Ethics approval and consent to participate

Non-applicable.

Consent for publication

Informed consent was obtained from the patient for publication of this case report and any accompanying images.

References

1. Danna BJ, Harvey AW, Woc-Colburn LE, 2020, Esophageal Tuberculosis-A Mass of Confusion. *Am J Med*, 133(10):e589–90. DOI: 10.1016/j.amjmed.2020.02.038.
2. Puri R, Khaliq A, Kumar M, *et al.*, 2012, Esophageal Tuberculosis: Role of Endoscopic Ultrasound in Diagnosis. *Dis Esophagus*, 25(2):102–6. DOI: 10.1111/j.1442-

- 2050.2011.01223.x.
3. Xiong J, Guo W, Guo Y, et al., 2020, Clinical and Endoscopic Features of Esophageal Tuberculosis: A 20-Year Retrospective Study. *Scand J Gastroenterol*, 55(10):1200–4. DOI: 10.1080/00365521.2020.1813799.
 4. Tang Y, Shi W, Sun X, et al., 2017, Endoscopic Ultrasound in Diagnosis of Esophageal Tuberculosis: 10-Year Experience at a Tertiary Care Center. *Dis Esophagus*, 30(8):1–6. DOI: 10.1093/dote/dox031.
 5. Dahale AS, Kumar A, Srivastava S, 2018, Esophageal Tuberculosis: Uncommon of Common. *JGH Open*, 2(2):34–8. DOI: 10.1002/jgh3.12043.
 6. Li YX, Nian WD, Wang HH, 2018, A Case of Esophageal Tuberculosis with Unusual Endoscopic Feature. *Clin Res Hepatol Gastroenterol*, 42(1):e5–6.
 7. Khan MS, Maan MH, Sohail AH, et al., 2019, Primary Esophageal Tuberculosis Mimicking Esophageal Carcinoma on Computed Tomography: A Case Report. *World J Gastrointest Surg*, 11(9):373–80. DOI: 10.4240/wjgs.v11.i9.373.
 8. Mao L, Zhou XT, Li JP, et al., 2020, Esophageal Tuberculosis Complicated with Intestinal Tuberculosis: A Case Report. *World J Clin Cases*, 8(3):645–51.
 9. Zhu R, Bai Y, Zhou Y, et al., 2020, EUS in the Diagnosis of Pathologically Undiagnosed Esophageal Tuberculosis. *BMC Gastroenterol*, 20(1):291. DOI: 10.1186/s12876-020-01432-7.
 10. Kocaman O, Sentürk H, Danalıoğlu A, et al., 2013, Endosonography and Elastography in the Diagnosis of Esophageal Tuberculosis. *Turk J Gastroenterol*, 24(3):290–1. DOI: 10.4318/tjg.2013.0488.
 11. Han XM, Yang JM, Xu LH, et al., 2008, Endoscopic Ultrasonography in Esophageal Tuberculosis. *Endoscopy*, 40(8):701–2.